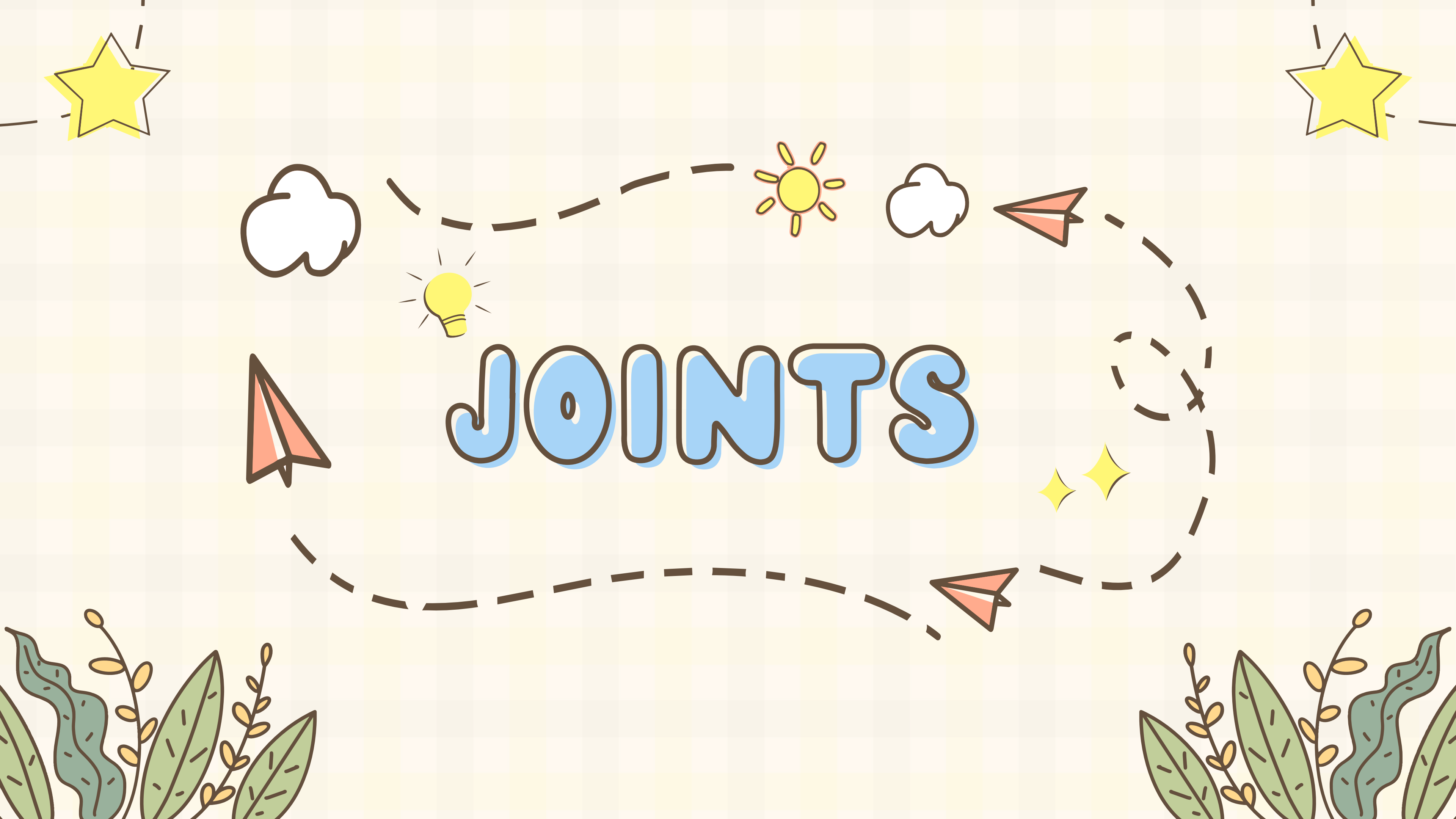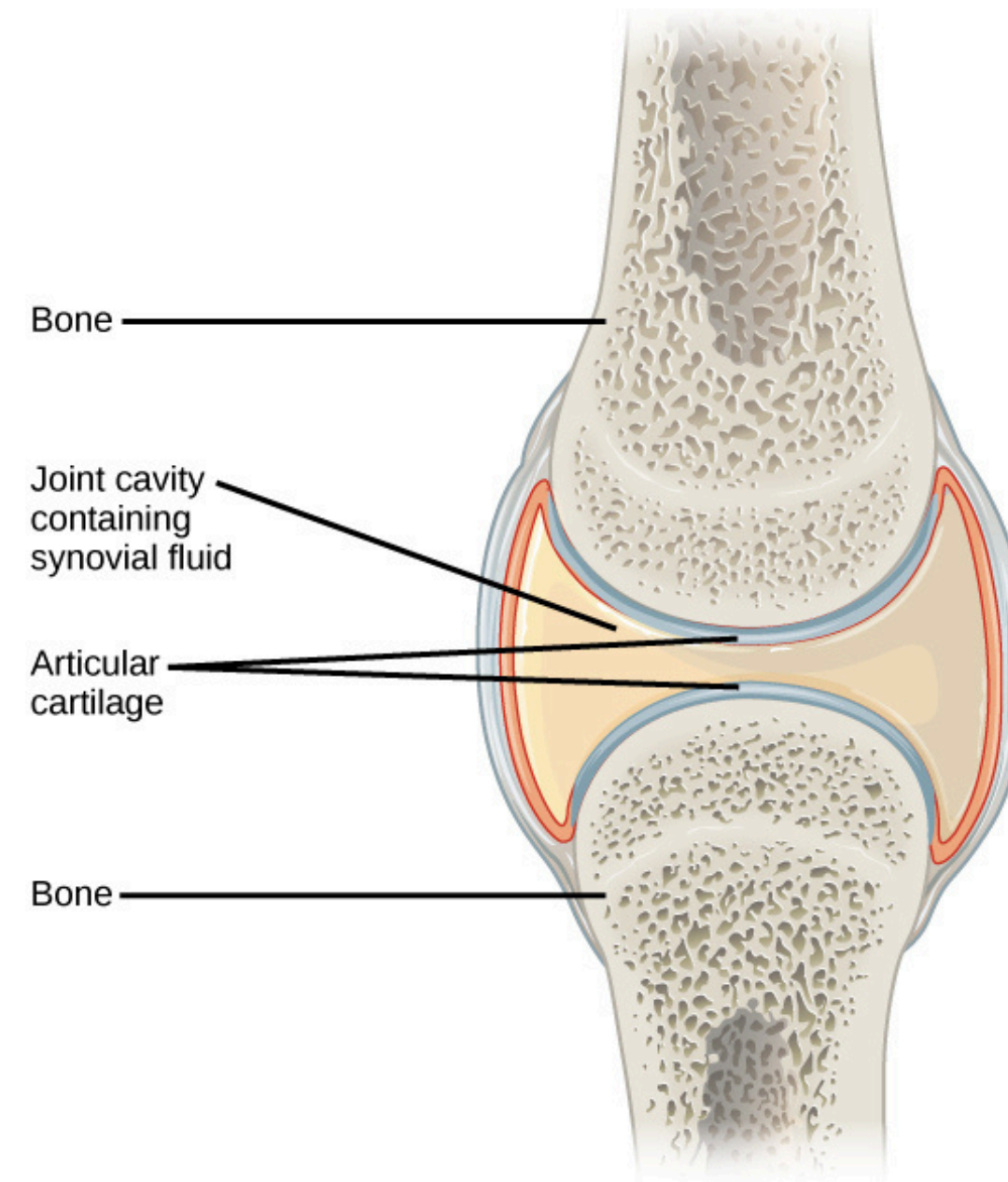




JOINTS

WHAT IS A JOINT?


a.k.a. articulation

This is where two bones meet
They hold the skeleton together and allow
it to move easily






FUNCTIONAL



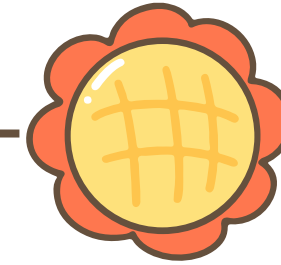
SYNARTHROSES

Immovable joint
Ex: fibrous, cartilage



AMPHIARTHROSES

Slightly movable joints
Ex: cartilage, fibrous




DIARTHROSES

Freely movable joints
Ex: synovial joints





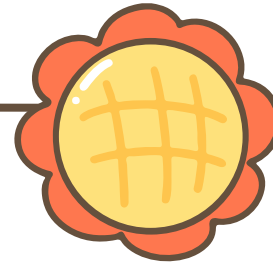
STRUCTURAL



FIBROUS

dense fibrous connective tissue
no joint cavity
immovable

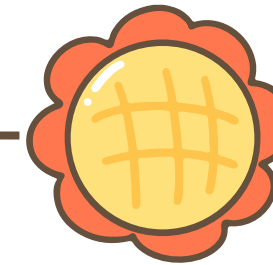
Types: sutures, syndesmoses, and
gomphoses



CARTILAGINOUS

has cartilage
no joint cavity
immovable

Types: synchondroses and
symphyses

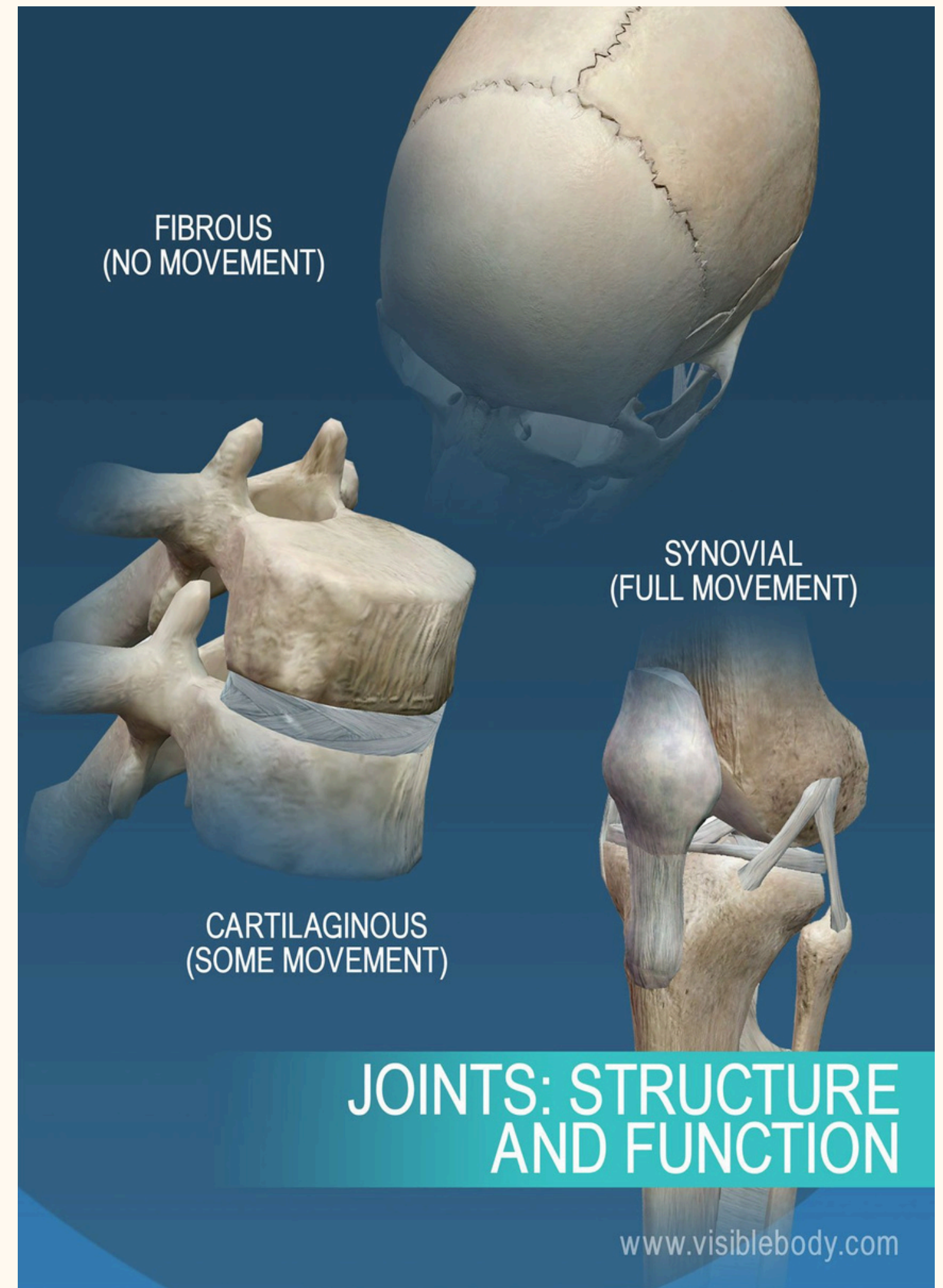
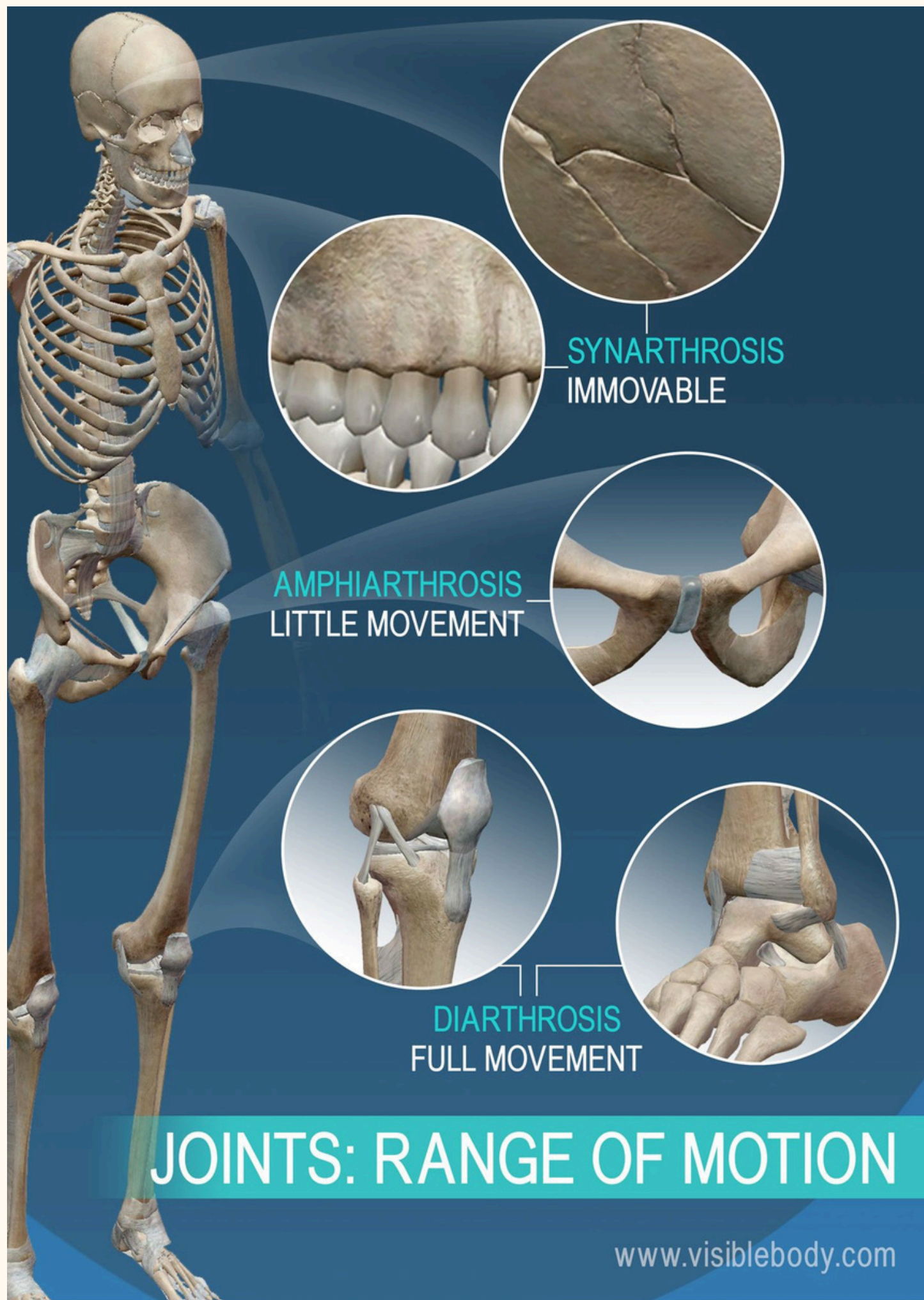

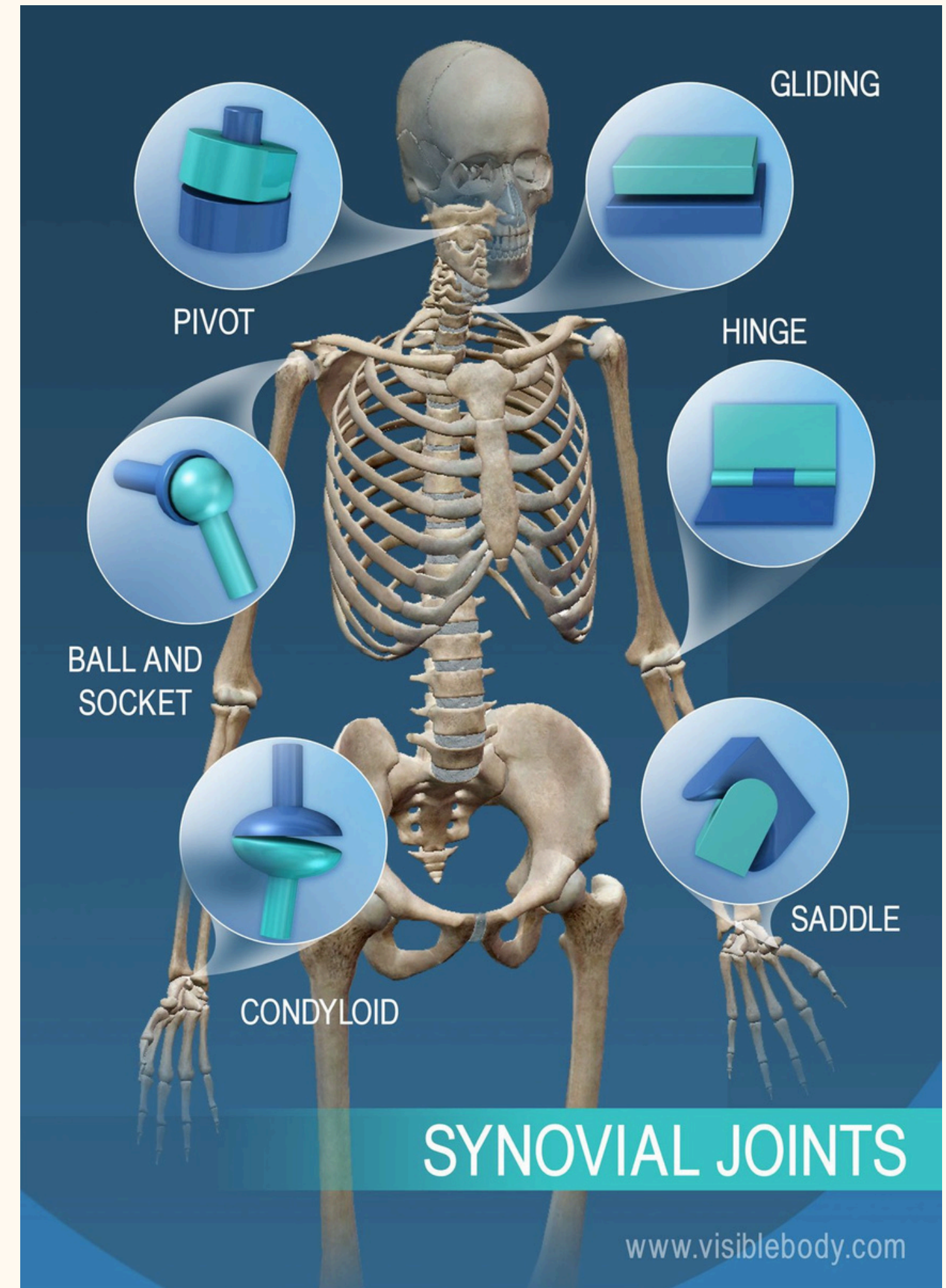
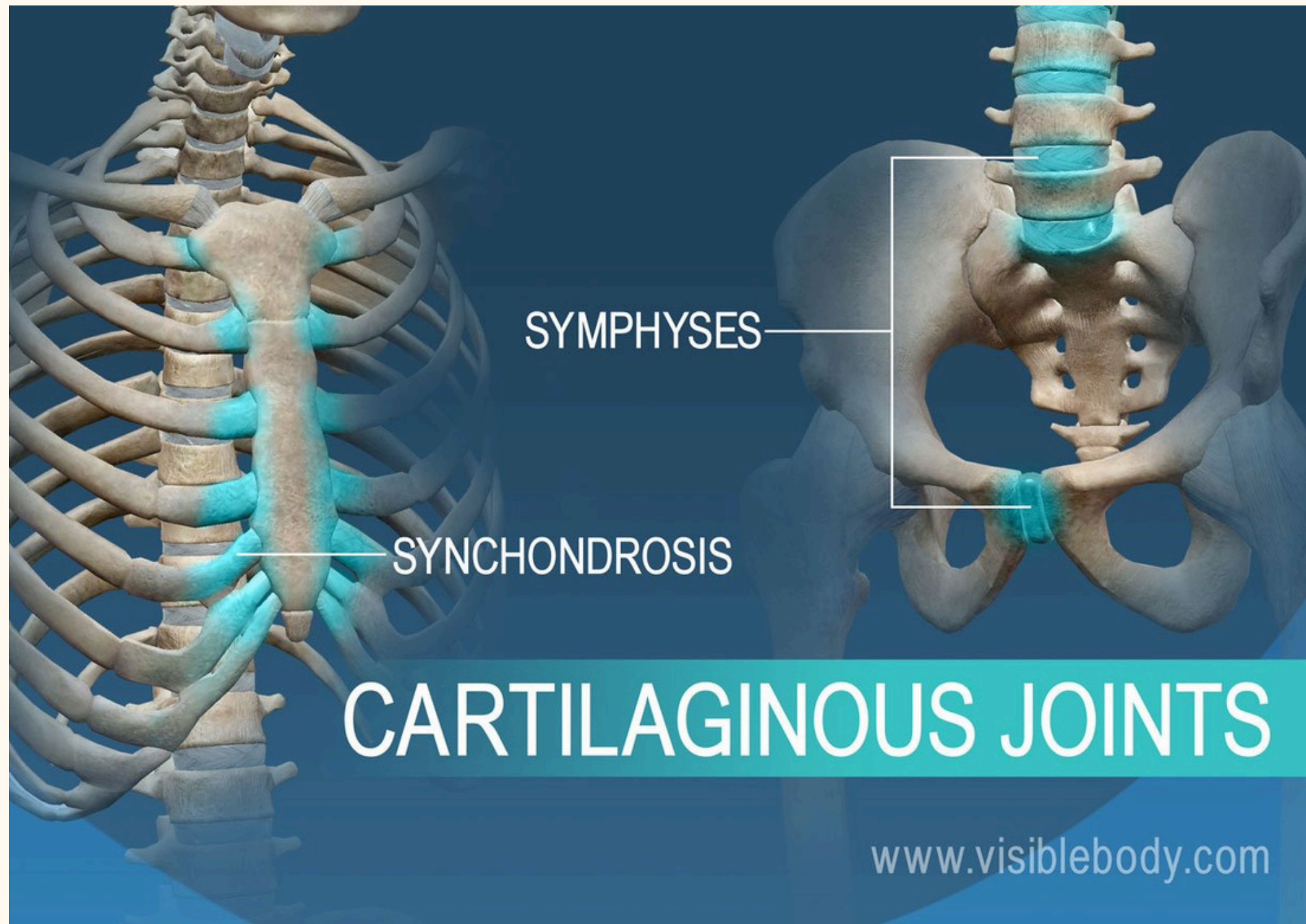
SYNOVIAL

separated by fluid joint cavity
freely movable
almost all limb joints

Types: plane, hinge, pivot,
condylar, saddle, ball-and-socket









FEATUERS

Articular cartilage

Hyaline cartilage
prevents crushing

Joint cavity

fluid-filled space only to
synovial joints

Articular capsule

External fibrous layer (dense
irregular connective)
Internal synovial membrane
(loose connective, makes
synovial fluid)

Synovial fluid



plasma and hyaluronic acid
lubricate and nourishes
articular cartilage
has phagocytic cells

Reinforcing ligaments

Capsular layer (thick part)
Extracapsular layer (outside)
Intracapsular layer (inside)

Other

Fatty pads, articular discs
(menisci), Bursae, Tendon
sheaths





JOINT INJURIES

Cartilage Tears

Caused by stress
Repaired by
arthroscopic surgery

Sprains

Caused by joint being
stretched or torn
Repaired by surgery, grafts,
and immobilization
Inflammation

Dislocations

Bones forced out of
of alignment

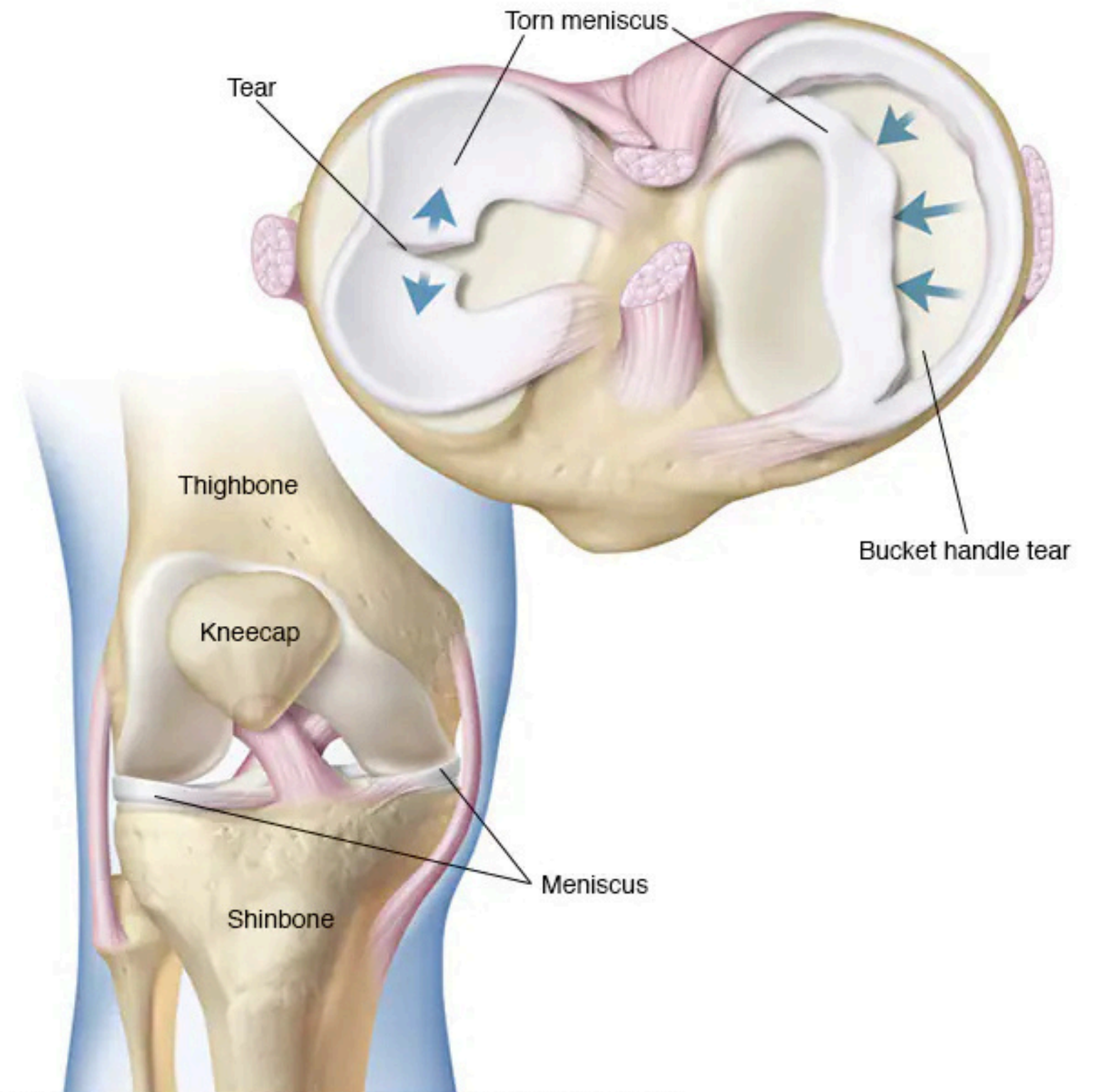
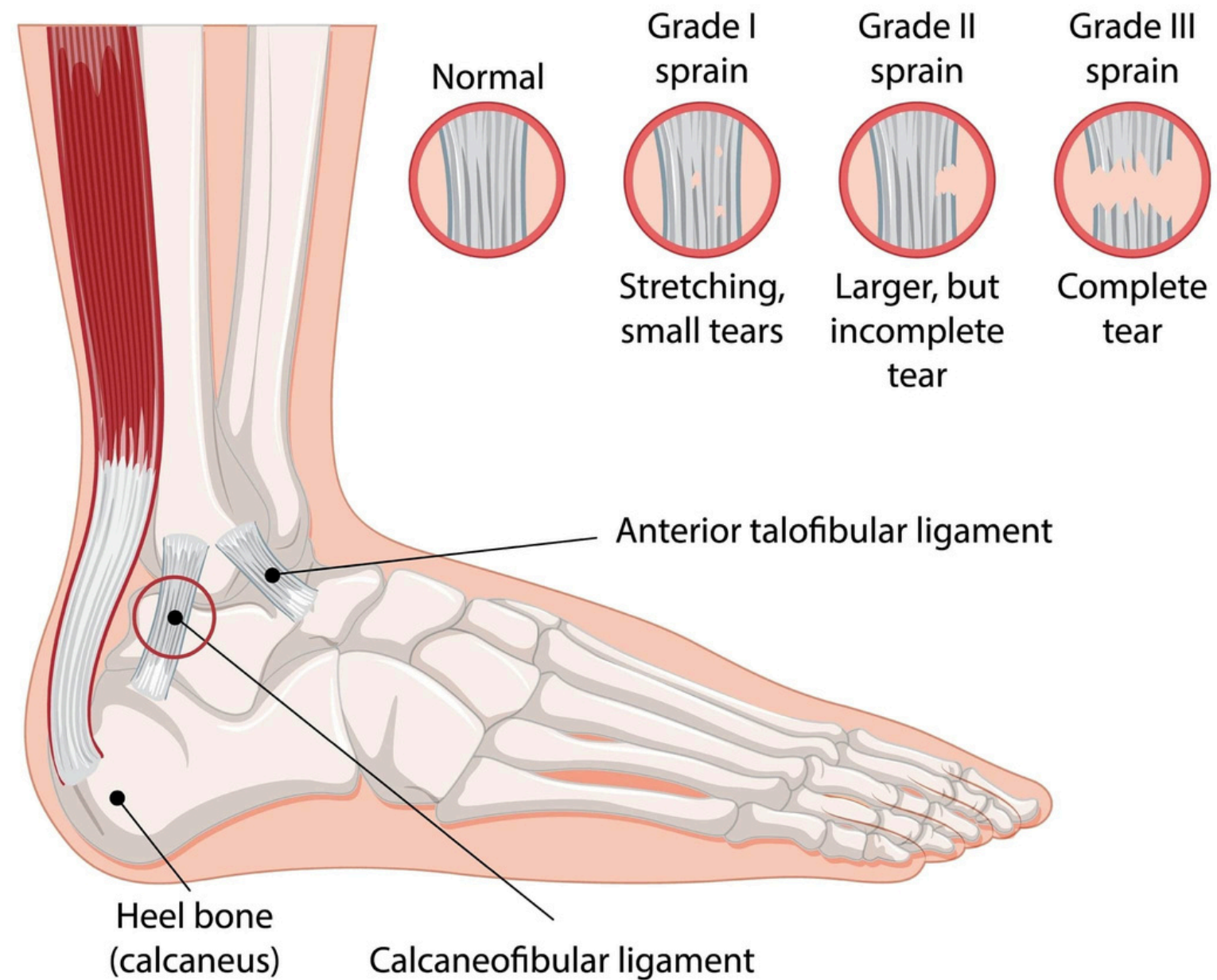
Subluxation

partial dislocation of
a joint



Ankle Sprain

Injury to the ligaments that support the ankle, often caused by twisting or rolling the ankle.



© MAYO FOUNDATION FOR MEDICAL EDUCATION AND RESEARCH. ALL RIGHTS RESERVED.

Cartilage tear (meniscus tear)

CONDITIONS

Itis = Inflammation

Bursitis



Inflammation of bursa
caused by blow or friction

Tendonitis



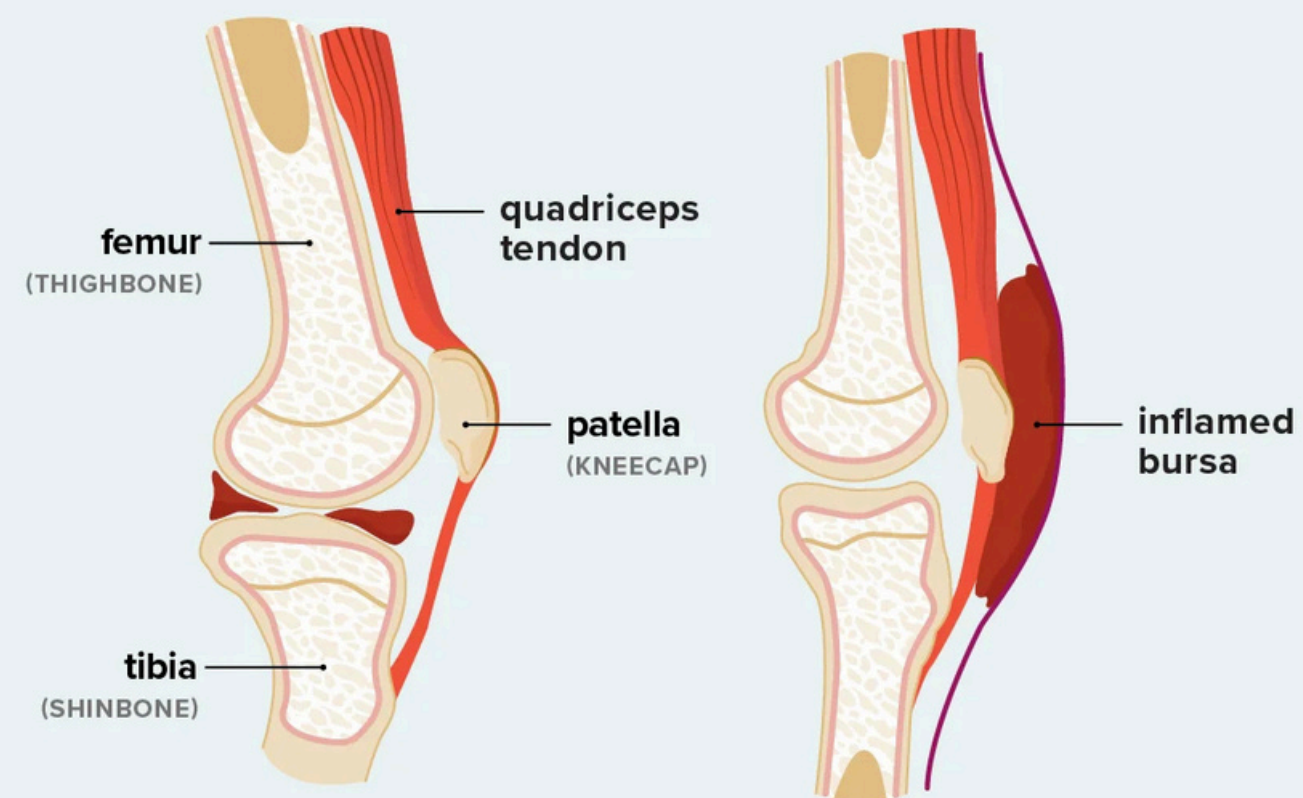
Inflammation of tendon sheaths
caused by overuse

Arthritis

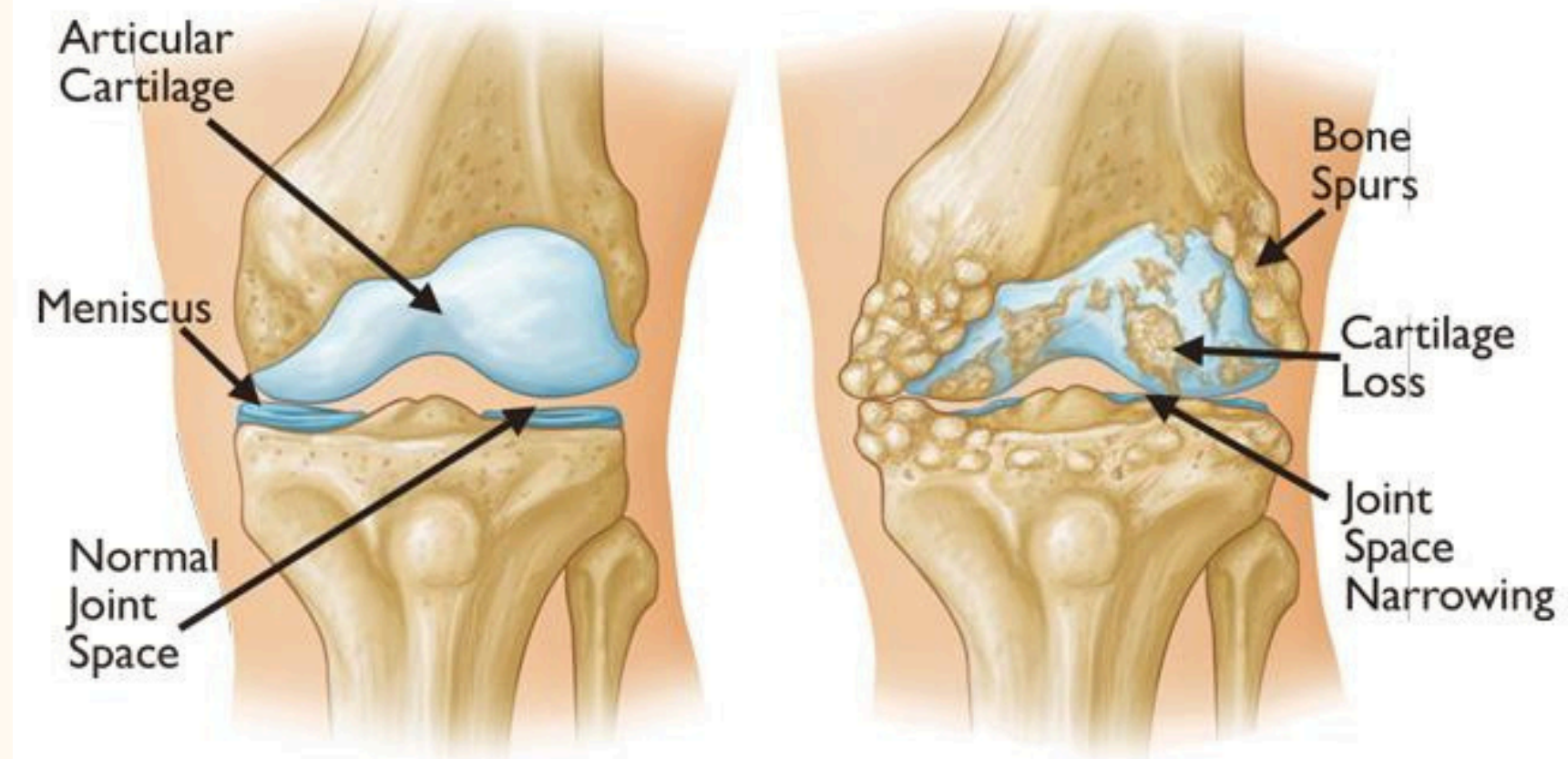


swelling of joint
caused by bacteria, treated by antibiotics
Forms: **Osteoarthritis, Rheumatoid
arthritis, Gouty arthritis**

Bursitis



healthline



Healthy
Achilles Tendon

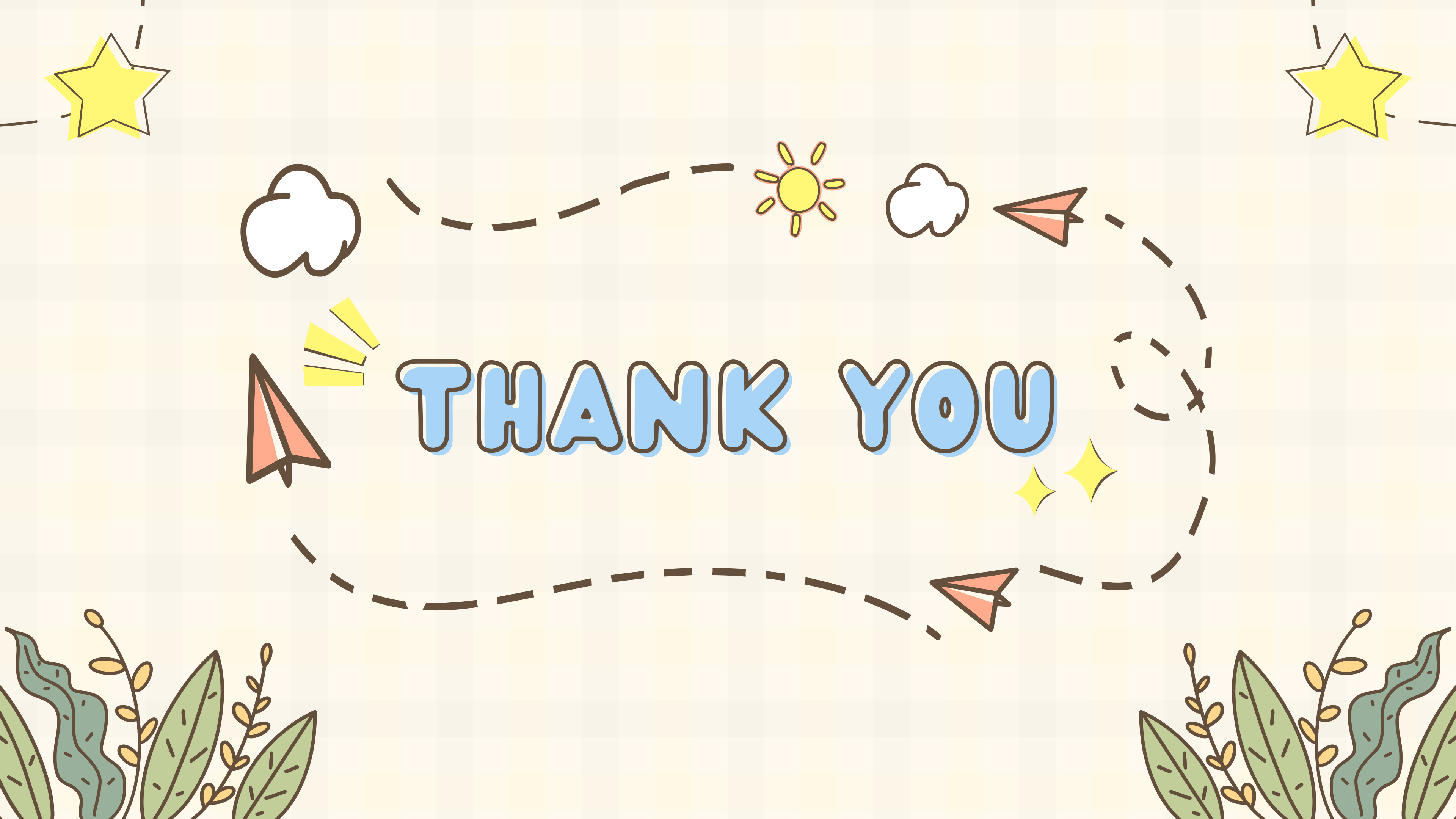Tendonitis

Inflammation

Tendonosis

Degeneration

Cleveland
Clinic
©2021



THANK YOU